

Oral Medication Guidelines – Acute angle closure

Description

Acute angle closure (AAC) arises from a pre-existing iris configuration, causing pupillary block. The underlying mechanism of AAC is the mechanical obstruction of aqueous humour outflow through the trabecular meshwork by the peripheral iris. Risk factors for AAC include hyperopia and a shallow anterior chamber (Rhee, & the Wills Eye Hospital, 2003).

Significance

AAC is an ophthalmic emergency and appropriate therapy needs to be initiated immediately in order to prevent vision loss. The fellow eye also requires prompt treatment in order to prevent future attacks.

Incidence

The incidence of AAC varies widely between genders and ethnicities. One study of a large, primarily Caucasian population found the incidence per annum was 2.46 per 100,000 for males, and 5.65 per 100,000 for females aged over 30 years (Ramesh, *et.al.*, 2005). The incidence of AAC is higher amongst Asian and Inuit populations (Ramesh, *et.al.*, 2005). AAC is particularly common in Singapore with a reported incidence of 12.2 per 100,000 per annum in individuals aged over 30 (Ang *et.al.*, 2000). The incidence of AAC is lower in African populations (Rhee, & the Wills Eye Hospital, 2003).

Management category

The management of AAC is undertaken by ophthalmologists - an optometrist who makes a diagnosis of AAC must immediately refer the patient for ophthalmologic assessment and treatment. In some cases, initial pharmacological management, including topical and oral medications, may need to be initiated by the referring optometrist (this will be further outlined below).

Even following the resolution of an attack of AAC, patients are considered glaucoma suspects and require life-long follow-up care.

Signs and symptoms

An acute angle closure attack is almost always unilateral. Symptoms are more likely to occur in dim illumination (Rhee, & the Wills Eye Hospital, 2003).

Typical symptoms of acute angle closure include (Friedman & Kaiser, 2009):

- redness

- pain (can range from mild to severe)
- blurred vision
- halos around lights
- tearing
- photophobia
- nausea and vomiting
- headache.

Typical signs of acute angle closure include (Friedman & Kaiser, 2009):

- increased intraocular pressure
- ciliary injection
- corneal oedema
- anterior chamber cells and flare
- shallow anterior chamber
- closed angles on gonioscopy
- mid-dilated non-reactive pupil
- iris bombé.

Signs of previous attacks may also be present. These can include:

- sectoral iris atrophy
- anterior subcapsular lens opacities
- dilated irregular pupil
- peripheral anterior synechiae.

Differential diagnoses

The main differential diagnosis is anterior uveitis. The patient with uveitis is likely to have a miotic pupil, rather than the mid-dilated pupil observed in AAC. Intraocular pressure (IOP) in anterior uveitis may be normal, reduced or increased. Posterior synechiae may be observed in anterior uveitis. The anterior chamber reaction is more marked in anterior uveitis and hypopyon may be present (Friedman & Kaiser, 2009).

Other differential diagnoses to consider include Posner-Schlossman syndrome (glaucomatocyclitic crisis), secondary angle closure (for example angle closure caused by iris neovascularisation or a tumour) and iridocorneal endothelial (ICE) syndrome.

Management

The aims of treatment of AAC are to lower IOP, prevent damage to the optic nerve and improve patient comfort (Emanuel, *et.al.*, 2014). The treatment for AAC includes the following:

- Breaking the acute attack with medical therapy, laser therapy or surgery.
- Laser peripheral iridotomy or surgical iridectomy (usually after the IOP has been lowered medically).

- Evaluation and treatment of the fellow eye.
- IOP should be reviewed every 15 to 30 minutes.

1. Topical treatment

Immediately following the diagnosis of AAC, the patient should receive the following topical medications in the affected eye (provided there are no existing contraindications):

- Topical β -blocker (timolol maleate 0.5%) – one drop is instilled in the affected eye at the time of diagnosis. Betaxolol 0.25% or 0.5% eye drops can be used instead of timolol in patients with pulmonary contraindications.
- Topical α -agonist (apraclonidine 0.5%) – The recommended dose of apraclonidine is one drop in the affected eye at the time of diagnosis.
- Topical miotic (pilocarpine 1-2%) – Pilocarpine is not effective if the IOP is >40 mmHg due to iris sphincter ischaemia. In up to 20% of patients, pilocarpine can cause forward displacement of the lens-iris diaphragm. Concentrations greater than 2% are generally not used, as they are more likely to increase pupillary block. Pilocarpine can be administered even when the IOP is > 40 mmHg - Pilocarpine may be administered every 15 to 60 minutes, for a total of 2 to 4 doses (Hillman, 1979).

In addition to these standard topical medications, the following eye drops can also be used:

- Topical prostaglandin analogue (bimatoprost 0.03%, travoprost 0.004%, latanoprost 0.005%) – One drop is instilled in the affected eye at presentation.
- Topical carbonic anhydrase inhibitor (CAI) (brinzolamide 1%) – One drop in the affected eye at presentation. The topical CAI may have a limited effect as the patient will also be commenced on oral CAI therapy. However, the oral CAI may take up to two hours to have a significant effect on IOP.

Following initial treatment with the above IOP-lowering medications, if the eye is acutely inflamed, then a topical corticosteroid (prednisolone 1% or dexamethasone 0.1%) can be instilled up to four times per day (Salmon, 2020). It is well-documented that topical corticosteroids, particularly potent steroids, can cause an increase in IOP. Patients will already be closely monitored in the period following diagnosis with AAC, and IOP measurement will be part of every assessment.

2. Oral treatment

Oral treatment is provided concurrently with topical medication in an AAC crisis. The oral carbonic anhydrase inhibitor (CAI), acetazolamide, is used to lower IOP. 500 mg (two 250 mg tablets) of acetazolamide is given at initial presentation (this can be prescribed by the accredited optometrist if it is going to take more than 1 to 2 hours for the patient to receive ophthalmological care). Acetazolamide 500 mg is then administered twice daily until adequate IOP control (< 20 mmHg) is reached.

3. Intravenous treatment

Intravenous hyperosmotic agents are also effective at reducing IOP during AAC attacks, particularly if the patient is not responding to topical and oral medication. Intravenous 20% mannitol can be given at a dose of 1-2 g/kg over 24 hours. A modified dose is used for patients with renal failure.

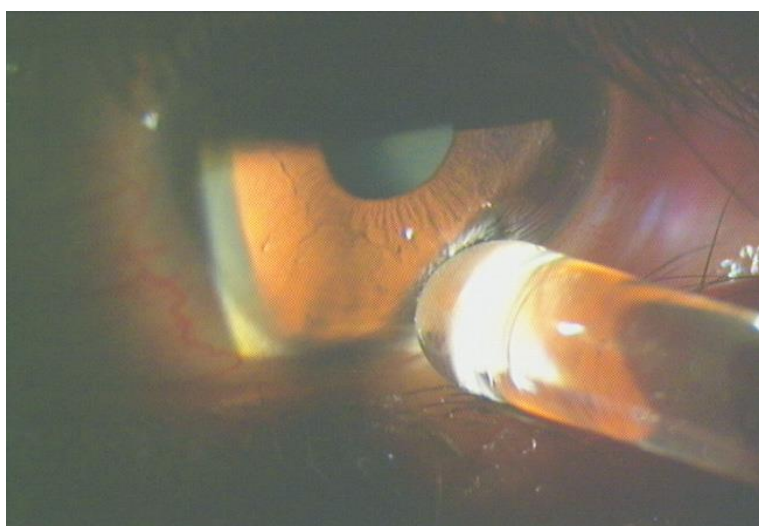
Acetazolamide, via intravenous infusion can also be used at a dose of 250 mg every four hours.

4. Corneal indentation

As medical management of AAC can sometimes take a significant amount of time to achieve IOP reduction and pain relief, corneal indentation may be used as a technique to help control IOP by deepening the anterior chamber angle. Corneal indentation can be performed, after the instillation of topical anaesthetic, using a number of different instruments including a cotton bud, a glass rod and a gonioscope (small diameter gonioscopy lens) (Masselos, *et.al*, 2009). The cornea is indented with sufficient pressure to force the aqueous peripherally into the anterior chamber drainage angle. This displaces the iris posteriorly from the trabecular meshwork (Masselos, *et.al*, 2009). If using a gonioscope, the central cornea is indented. If the examiner is using a glass rod or cotton bud, the pressure is applied to the inferior cornea. Indentation can be performed for 30 seconds, with a break of 30 seconds, followed by another 30 seconds of pressure. A reduction in IOP can be expected after three to four cycles (Masselos, *et.al*, 2009).

Figure 1 (below) shows the mid-peripheral inferior corneal indentation using a glass rod (Salmon, 2020)

Figure 1



5. Laser and surgical treatment

A sufficiently clear cornea is required in order to be able to undertake laser peripheral iridotomy treatment to the affected eye.

It is imperative to treat the fellow eye, as the patient is at risk of developing AAC in this eye (Emanuel *et.al.*, 2014). A prophylactic laser peripheral iridotomy is performed in the fellow eye, in order to prevent future attacks. Some patients may be reluctant to have the unaffected eye treated during an acute attack.

Laser iridoplasty (also called goniotomy), uses low energy laser burns to the peripheral iris to widen the anterior chamber angle in AAC (Weiss *et.al.*, 1992). This technique may be effective in treating cases of AAC that are unresponsive to medical management, particularly if there is persistent corneal oedema. Laser peripheral iridotomy will still be required when the corneal oedema has resolved. Laser iridoplasty is useful in the management of patients with plateau iris syndrome (who have already undergone a peripheral iridotomy) (Ramakrishnan *et.al.*, 2016).

Warnings and precautions

- Acetazolamide use is contraindicated in patients with known hypersensitivity to sulfonamides or derivatives, marked renal or hepatic impairment. Allergy to sulfur is not the same as sulfonamide allergy – patients with an allergy to sulfonamide medications (eg. Acetazolamide) are not necessarily allergic to other medications containing sulfur derivatives (eg. Sulfites, sulfates and sulfhydryl containing drugs). Acetazolamide is not known to have harmful effects on the human foetus. However, animal studies have shown evidence of an increased occurrence of foetal damage.
- Timolol is contraindicated in patients with obstructive lung disorders, uncontrolled heart failure and severe bradycardia. It should be used with caution in patients with asthma, diabetes, or cardiovascular disease. Beta adrenergic blocking agents, including timolol may cause pharmacological effects such as bradycardia in the human foetus.
- The use of apraclonidine is contraindicated in patients with severe, uncontrolled cardiovascular disease. Apraclonidine should be used with caution in patients with Parkinson's disease, renal impairment, or hepatic impairment. However, in an acute setting such as a patient presenting with AAC, one drop is unlikely to have a significant deleterious effect.
- Pilocarpine should be used with caution in patients susceptible to retinal detachment.
- Brinzolamide is contraindicated in patients with sulfonamide hypersensitivity and should be used with caution in renal impairment. Brinzolamide is not known to have harmful effects on the human foetus, however, animal studies have shown evidence of an increased occurrence of foetal damage.
- Prostaglandin analogues may have some mild pro-inflammatory effects in AAC. However, the priority is to reduce the IOP and improve patient comfort as quickly as possible. The effect of topical prostaglandin analogues on the human foetus is not known. However, some suggest avoiding the use of these eye drops in the first trimester. It is unlikely there would be any significant systemic effect due to the extremely small systemic dosage.
- Topical corticosteroids are contraindicated in cases of microbial eye infections. Use a high level of caution in patients with a history of epithelial herpes simplex keratitis.
- Intravenous mannitol is contraindicated in patients with severe renal disease, pulmonary congestion, and severe heart failure.

Adverse effects:

- The use of acetazolamide is associated with several adverse effects: paresthesia ('pins and needles') and polyuria (increased urine production) are almost universally reported with acetazolamide use. Other adverse effects include loss of appetite, increased thirst, fatigue, dizziness, headache, skin reactions, gastrointestinal upset, and central nervous system effects.
- Adverse effects of timolol include bradycardia, hypotension, bronchospasm, cough, depression, nightmares, and decreased libido.
- The use of apraclonidine is associated with several possible adverse effects, including taste disturbance, drowsiness, nervousness and irritability.
- Common adverse effects of pilocarpine use include headache and blurred vision. Use of this medication can also cause gastrointestinal upset.
- The use of brinzolamide is associated with several possible adverse effects including blurred vision, dysgeusia (metallic taste) and headache.
- The common adverse effects of prostaglandin analogues (increased lash growth and darkness, periorbital pigmentation, orbital fat atrophy and increased iris pigmentation) should not occur with short term usage such as in the setting of AAC.
- Topical ophthalmic corticosteroids are associated with a number of possible adverse effects, the likelihood of which increases with more intensive dosing or longer-term use. The potential for IOP increase has already been mentioned. Additionally, use of topical corticosteroids has been associated with posterior subcapsular cataract, secondary infection, and ptosis, among others (McGhee *et.al.*, 2002).

Referral Criteria

All patients with AAC should be referred immediately to an ophthalmologist. The examining optometrist may initiate topical treatment at the time of patient presentation after phone consultation with an ophthalmologist. Non-therapeutically qualified optometrists can initiate topical treatment following consultation with an ophthalmologist and receipt of a emailed prescription from the ophthalmologist. For optometrists, consultation with an ophthalmologist should precede oral treatment. Optometrists should initiate oral treatment for AAC only if the patient is unable to be promptly examined by an ophthalmologist; for example, if the patient presents to an optometrist in a rural setting and it will take several hours to reach the nearest hospital.

Informed consent

As with all healthcare interventions, the optometrist is responsible for ensuring that the patient has been advised of the possible risks and benefits associated with the prescription medication, in order that the patient can make an informed decision and provide consent to the treatment plan.

References

- Ang, L.P., Aung, T., Chew, P.T. (2000). Acute primary angle closure in an Asian population: long-term outcome of the fellow eye after prophylactic laser peripheral iridotomy. *Ophthalmology*, 107 (1), 2092-2096.
- Emanuel, M.E., Parrish, R.K. 2nd, Gedde, S.J. (2014). Evidence-based management of primary angle closure glaucoma. *Current opinion in ophthalmology*, 25:89-92.
<https://doi.org/10.1097/ICU.0000000000000028>
- Emanuel, M.E., Parrish, R.K. 2nd, Gedde, S.J. (2014). Evidence-based management of primary angle closure glaucoma. *Current opinion in ophthalmology*, 25:89-92.
<https://doi.org/10.1097/ICU.0000000000000028>
- Friedman, N.J., & Kaiser, P.K. (2009). The Massachusetts Eye and Ear Infirmary Illustrated Manual of Ophthalmology (3rd ed). USA: Saunders Elsevier
- Hillman, J.S. (1979). Acute closed-angle glaucoma: an investigation into the effect of delay in treatment. *British journal of ophthalmology*, 63:817-821
- Masselos, K., Bank, A., Francis, I.C., Stapleton, F. (2009) Corneal indentation in the early management of acute angle closure. *Ophthalmology*, 116:25-29.
<https://doi.org/10.1016/j.ophtha.2008.08.032>
- McGhee, C.N., Dean, S, Danesh-Meyer, H. (2002). Locally administered ocular corticosteroids: benefits and risks. *Drug safety*, 25:33-55. <https://doi.org/10.2165/00002018-200225010-00004>
- Ramakrishnan, R., Mitra, A., Abdul Kader,M., Das, S. (2016). To study the efficacy of laser peripheral iridoplasty in the treatment of eyes with primary angle closure and plateau iris syndrome, unresponsive to laser peripheral iridotomy, using anterior-segment OCT as a tool. *Journal of glaucoma*, 25:440-446. <https://doi.org/10.1097/IJG.0000000000000307>
- Ramesh, S., Maw C., Sutton C.J., Gandhewar, J.R., Kelly, S.P. (2005). Ethnic aspects of acute primary angle closure in a UK multicultural conurbation. *Eye*, 19 (1), 1271-1275.
<https://doi.org/10.1038/sj.eye.6701759>
- Rhee, D. J., the Wills Eye Hospital. (2003). Color Atlas and Synopsis of Clinical Ophthalmology - Glaucoma. USA: McGraw-Hill.
- Salmon, J.F. (2020). Kanski's clinical ophthalmology: a systematic approach, 9th edition: Elsevier. Edinburgh
- Weiss, H.S., Shingleton, B.J., Goode, S.M., Bellows, A.R., Richter, C.U. (1992). Argon laser goniotomy in the treatment of angle-closure glaucoma. *American journal of ophthalmology* 114:14-18.

Acknowledgements:

The Board thanks the following people for their contributions to developing the Board's oral medicine guidelines: Dr Nicola Anstice, Professor Jennifer Craig, Professor Helen Danesh-Meyer, Dr Simon Dean, Dr Hannah Kersten, Professor Charles McGhee and Mr Ross Tayler.

Approved by the Board: 2015

Updated by Board: 2022 (V2)

To be reviewed: 2025